

# Effect of acute intraocular pressure elevation on the minimum rim width in normal, ocular hypertensive and glaucoma eyes

Sourabh Sharma,<sup>1</sup> Tin A Tun,<sup>1,2</sup> Mani Baskaran,<sup>1,3</sup> Eray Atalay,<sup>1</sup> Sri Gowtham Thakku,<sup>1</sup> Zhang Liang,<sup>2,4</sup> Dan Milea,<sup>1,3</sup> Nicholas G Strouthidis,<sup>1,5,6</sup> Tin Aung,<sup>1,3,7</sup> Michael JA Girard<sup>1,2</sup>

<sup>1</sup>Singapore National Eye Center, Singapore Eye Research Institute, Singapore, Singapore

<sup>2</sup>Ophthalmic Engineering & Innovation Laboratory, Department of Biomedical Engineering, National University of Singapore, Singapore, Singapore

<sup>3</sup>Duke-NUS Graduate Medical School, National University of Singapore, Singapore, Singapore

<sup>4</sup>NUS Graduate School for Integrative Sciences and Engineering, National University of Singapore, Singapore, Singapore

<sup>5</sup>NIHR Biomedical Research Centre, Moorfields Eye Hospital NHS Foundation Trust and UCL Institute of Ophthalmology, London, UK

<sup>6</sup>Discipline of Clinical Ophthalmology and Eye Health, University of Sydney, Sydney, NSW, Australia

<sup>7</sup>Department of Ophthalmology, Yong Loo Lin School of Medicine, National University of Singapore, Singapore, Singapore

## Correspondence to

Dr Michael JA Girard, Ophthalmic Engineering & Innovation Laboratory (OEIL), Department of Biomedical Engineering, National University of Singapore, 4 Engineering Drive 3, E4-04-08, 117583, Singapore; [mgirard@nus.edu.sg](mailto:mgirard@nus.edu.sg)

Received 24 January 2017

Revised 6 April 2017

Accepted 11 April 2017

## ABSTRACT

**Background** To estimate and compare changes in the Bruch's membrane opening—minimum rim width (BMO–MRW) and area in normal, ocular hypertensive and glaucoma eyes following acute elevations in intraocular pressure (IOP).

**Methods** The optic nerve heads (ONHs) of 104 subjects (31 normals, 20 ocular hypertension (OHT) and 53 with primary glaucoma) were imaged using Spectral-domain optical coherence tomography (OCT; Spectralis, Heidelberg Engineering, Germany). IOP was raised twice by applying a force (0.64 n then 0.9 n) to the anterior sclera using an ophthalmodynamometer. After each IOP increment, IOP was held constant, measured with a Tonopen (AVIA applanation tonometer, Reichert, Depew, New York, USA), and ONH was rescanned with OCT. In each OCT volume, BMO–MRW and area were calculated and at each IOP increment.

**Results** The baseline MRW was significantly smaller in glaucoma subjects ( $174.3 \pm 54.3 \mu\text{m}$ ) compared with normal ( $287.4 \pm 42.2 \mu\text{m}$ ,  $p < 0.001$ ) and OHT subjects ( $255.4 \pm 45.3 \mu\text{m}$ ,  $p < 0.001$ ). MRW of glaucoma subjects was significantly thinner at the first and second IOP elevations than that at baseline (both  $p < 0.01$ ), but no significant change was noted in normal and OHT subjects. There was no significant change of BMO area at acute IOP elevations from baseline in all diagnoses (all  $p > 0.05$ ).

**Conclusion** Acute IOP elevation leads to compression of the nerve fibre layers of neuroretinal rim in glaucoma subjects only without changing ONH size. This suggests that the neural and connective tissues at ONH level in glaucoma subjects are more susceptible to acute IOP episodes than OHT or normal controls.

## INTRODUCTION

Given that current intraocular pressure (IOP) lowering strategies with medications, laser or surgery are, to date, the only proven methods to slow the progression of glaucoma.<sup>1,2</sup> It is reasonable to assume that IOP plays an important role in the pathophysiology of the disease process. However, the mechanisms whereby IOP induces the development and progression of glaucomatous optic neuropathy (GON) are not well understood. Biomechanically, IOP-induced stress and strain are thought to play a major role in the progressive damage and remodelling of the optic nerve head

(ONH) tissues seen in GON.<sup>3</sup> There is a wide range of individual susceptibility of the ONH to IOP variations. Although resilience of the optic nerve against abnormally high pressure is noted in some eyes with ocular hypertension (OHT), other eyes show progressive damage even with normal IOP.<sup>4</sup> This difference could be due, at least in part, to differences in ONH morphology, microstructural organisation and biomechanical properties.

Previous research into the biomechanical properties of the ONH that have analysed the impact of acute IOP changes on the ONH, mostly at subsurface levels including the lamina cribrosa (LC), have shown inconsistent results.<sup>5–7</sup> It is important to note that the acute mechanical response of the ONH incorporates changes in the prelaminar neural tissues along with the LC. Moreover, the presence of LC signals are not always reliable and deeper optical coherence tomography (OCT) images of the ONH are often of variable quality. Thus, not all LC features are sufficiently visible to be used in clinical glaucoma management.<sup>8</sup>

Recently, Bruch's membrane opening (BMO)-derived neuroretinal rim parameters have been described by Reis *et al*.<sup>9</sup> BMO defines the anterior most boundary of the neural canal and commonly is the narrowest part of the neural canal. The shortest distance from BMO to the retinal internal limiting membrane (ILM), namely BMO–minimum rim width (BMO–MRW) is a clinically invisible parameter measured by OCT.<sup>10</sup> This parameter has been shown to have better diagnostic performance and better correlation to the visual field compared with traditional disc margin-based rim measures.<sup>11</sup> A recent study demonstrated decrease in BMO–MRW in primary angle-closure suspects (PACS) after acute IOP increase of more than 15 mm Hg by a dark room provocative test.<sup>12</sup>

In this study, we aimed to estimate and compare in vivo changes in the BMO–MRW in normal, hypertensive and glaucoma eyes following acute elevations in IOP. A better understanding of the acute mechanical responses of the nerve fibre layer (measured by BMO–MRW) to IOP elevations may be useful for improved glaucoma management.

## METHODS

### Subject recruitment

Chinese subjects above the age of 50 years were prospectively recruited from outpatient clinics of



CrossMark

**To cite:** Sharma S, Tun TA, Baskaran M, *et al*. *Br J Ophthalmol* Published Online First: [please include Day Month Year]. doi:10.1136/bjophthol-2017-310232

the Singapore National Eye Centre. The study adhered to the tenets of Declaration of Helsinki, and the SingHealth Centralised Institutional Review Board approved the study. Written informed consent was obtained from all subjects. Inclusion criteria were subjects with phakic eyes, with no known history of intraocular surgery and no history of penetrating eye trauma.

Enrolled subjects belonged to one of three groups:

1. Glaucoma group: primary open-angle glaucoma (POAG) or primary angle closure glaucoma (PACG). Glaucoma cases were defined by the presence of GON, defined as vertical cup:disc ratio of  $>0.7$  and/or neuroretinal rim narrowing with an associated visual field defect on standard automated perimetry, defined by the presence of at least three contiguous non-edge test points within the same hemifield on the pattern deviation probability plot at  $p < 5\%$  (with at least 1 point  $p < 1\%$ ) excluding points directly above and below the blind spot, with the presence of a glaucomatous hemifield test result and pattern SD outside normal limits ( $<0.05$ ), repeatable on two separate occasions; in association with a PACG or with a POAG. Standard reliability indices were used, including fixation losses  $\leq 20\%$ , false positives  $\leq 33\%$  and false negatives  $\leq 33\%$ . All glaucoma subjects had high IOP ( $>21$  mm Hg) at least one time after they were clinically diagnosed with GON.<sup>13</sup>
2. Ocular hypertension group: OHT was defined by the presence of elevated IOP ( $>21$  mm Hg) with the absence of GON or specific visual field loss.
3. Control group: defined by having IOP  $\leq 21$  mm Hg with open angles, healthy optic nerves, normal visual fields, no previous surgery and no family history of glaucoma.

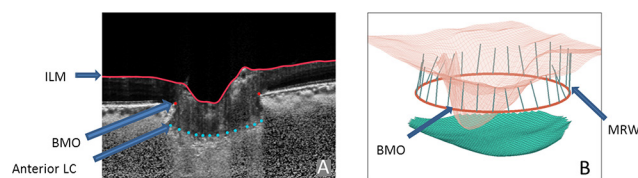
Subjects were excluded from the study if they were unable to give informed consent, if they had secondary glaucoma (such as uveitic, post-traumatic, pigmentary or neovascular glaucoma), severe glaucoma ( $< -12$  Db) or had either neurological or retinal disease with visual field defects. The patients with glaucoma were newly diagnosed or under pharmacological treatment, and the OHT subjects were untreated. All PACG eyes had undergone laser peripheral iridotomy prior to recruitment into the study. One eye of each eligible subject was considered for the study. If both eyes were eligible, one randomly selected eye was included for analysis.

### Clinical examination and acute elevations of IOP

All subjects underwent a standardised ophthalmic examination, the details of which are provided in our previous work.<sup>14</sup> The IOP of the study eye was raised twice by applying an external force through the temporal side of the lower eye lid using an ophthalmodynamometer (spring-loaded indenter).<sup>5 14</sup> The applied forces were consistently 0.64 n (82.5 g) and 0.9 n (95 g) as calibrated using a uniaxial tensile tester (Instron-5848, Instron, Norwood, Massachusetts, USA).

### OCT imaging and image processing

The ONH of each subject was imaged three times using Spectral-domain optical coherence tomography (SD-OCT): before increasing IOP (baseline) and once for each of the two IOP elevations (details provided in our previous work).<sup>14</sup> For each eye, postprocessed OCT volumes were then delineated by a single grader (TAT) using custom software developed in our laboratory. The BMO position was defined as the end point of the Bruch's membrane layer on either side of the ONH.<sup>15</sup> The ILM was delineated automatically from the Spectralis software. Using the aforementioned delineations, we reconstructed



**Figure 1** Images depicting Bruch's membrane opening (BMO) and minimum rim width (MRW) on the optic nerve head (ONH). (Reproduced with permission from<sup>15</sup>). (A) Cross-sectional or two-dimensional view of ONH with delineation of anterior lamina cribrosa (LC) and BMO. The red line indicates the internal limiting membrane, whereas the red dot designates the BMO. The anterior LC is shown by blue dotted points. (B) A three-dimensional reconstructive image of optic nerve head showing BMO (red ring) and MRW (green lines). ILM, internal limiting membrane.

the ONH structures in three-dimensional and used a previously described customised algorithm, coded in Matlab (Mathworks, Natick, Massachusetts, USA), to measure BMO–MRW automatically.<sup>16</sup> BMO–MRW is defined as the shortest distance from the BMO point to the ILM (figure 1A,B). Area measurements were also calculated for BMO after registering the marked optic disc images with en face infrared images of the optic disc. The quality of the SD-OCT image was assessed prior to the analysis, and images that were of insufficient quality (quality index of  $<25$  dB for SD-OCT, as suggested by the manufacturer, for the image quality assurance) were excluded.

### Statistical analysis

Statistical analyses were performed using SPSS statistics for Windows V.19.0. Continuous variables were described as the mean and SD. We used the analysis of variance (ANOVA) with Bonferroni correction to compare the differences in the means of continuous variables among groups and used the  $\chi^2$  test for categorical variables. Statistical significance was set at  $p < 0.05$ .

## RESULTS

### Demographic and clinical characteristics

A total of 117 Chinese subjects were recruited, out of which 13 individuals were excluded from the analysis (3 had tilted optic discs, 2 had large peripapillary atrophy, 7 had poor image quality due to cataract or uncorrectable blood vessel shadowing and 1 subject withdrew from the study). A total of 104 subjects (20 subjects with OHT, 53 with glaucoma (20 POAG and 33 PACG) and 31 normal controls) were, therefore, included in the final analysis.

Table 1 summarises the clinical and demographic characteristics of the enrolled subjects. The glaucoma subjects were significantly older and included more males than subjects with other diagnoses. They also had a higher visual field mean deviation than those with other diagnoses. The baseline IOP was significantly higher in OHT subjects ( $20.3 \pm 2.7$  mm Hg) than in glaucoma ( $17.4 \pm 3.6$  mm Hg) or normal controls ( $16.2 \pm 2.6$  mm Hg; table 1). The mean IOP of all study participants at baseline was found to be  $17.5 \pm 3.5$  mm Hg, which increased to  $37.7 \pm 6.0$ , then  $46.3 \pm 6.1$  mm Hg at first and second IOP elevation points, respectively. For each group, the IOP was significantly higher at first or second elevation than at baseline (all  $p < 0.001$ ; table 2).

### BMO–MRW—baseline values and changes with IOP elevations

BMO–MRW at baseline was significantly smaller in glaucoma subjects  $174.3 \pm 54.3 \mu\text{m}$  when compared with normal controls  $287.4 \pm 42.2 \mu\text{m}$  or OHT subjects  $254.6 \pm 45.3 \mu\text{m}$ . This

**Table 1** Demographic and clinical characteristics of the 104 study participants

Characteristics	Mean (SD) or n (%)			p-Value
	Normal (n=31)	OHT (n=20)	Glaucoma (n=53)	
Age, years	61.07 (5.59)	62.93 (7.23)	66.69 (7.10)	0.001*
Gender, female	23 (74.2)	13 (65.0)	17 (30.9)	<0.001†
IOP at baseline, mm Hg	16.29 (2.69)	20.35 (2.79)	17.43 (3.63)	<0.001‡
IOP at first elevation, mm Hg	37.29 (5.39)	41.05 (5.41)	37.01 (6.34)	0.031§
IOP at second elevation, mm Hg	45.16 (6.46)	47.80 (5.38)	46.45 (6.14)	0.31
Baseline BMO–MRW	287.46 (42.20)	254.67 (45.38)	174.36 (54.31)	<0.001¶
BMO–MRW at first elevation	280.82 (43.74)	253.36 (49.52)	166.85 (52.64)	<0.001¶
BMO–MRW at second IOP elevation	280.88 (42.36)	252.75 (51.90)	167.43 (52.63)	<0.001¶
Baseline BMO area	2.21 (0.38)	2.39 (0.75)	2.52 (0.64)	0.079
BMO area at first elevation	2.18 (0.38)	2.41 (0.75)	2.53 (0.65)	0.052
BMO area at second IOP elevation	2.18 (0.38)	2.36 (0.70)	2.52 (0.67)	0.054
Mean deviation of SAP, dB	–1.66 (1.72)	–2.38 (2.81)	–4.85 (4.13)	<0.001¶
Spherical equivalent, dioptre	–0.31 (3.17)	–0.83 (3.20)	–0.31 (3.24)	0.83
Vertical cup-disc ratio	0.40 (0.07)	0.53 (0.12)	0.75 (0.12)	<0.001†
Central corneal thickness, µm	550.03 (32.37)	557.17 (46.87)	549.65 (37.16)	0.61

\*p Value is significant between normal and glaucoma.

†p Value is significant in all pairwise comparisons.

‡p Value is significant between normal and OHT and between OHT and glaucoma.

§p Value is significant between OHT and glaucoma.

¶p Value is significant between normal and glaucoma and between OHT and glaucoma.

BMO, Bruch's membrane opening; MRW, minimum rim width; IOP, intraocular pressure; OHT, ocular hypertension; SAP, standard automated perimetry.

difference was also observed at both IOP elevation points (all  $p < 0.001$ ; table 1).

We found that with each incremental step in IOP, the mean scores for BMO–MRW were significantly reduced from baseline at first (mean difference  $-7.5 \mu\text{m}$ ,  $p < 0.001$ ) and second IOP elevations (mean difference  $-6.8 \mu\text{m}$ ,  $p = 0.003$ ) for the glaucoma group, but not for OHT ( $p < 0.86$ ) and normal controls ( $p < 0.13$ ) (table 2). For the second IOP increment, BMO–MRW

did not change significantly from first IOP increment for all diagnoses (all  $p > 0.05$ ).

#### BMO area—baseline values and changes with IOP elevations

The mean BMO area at baseline was larger in glaucoma subjects than in OHT or normal controls but the difference was not statistically significant (table 1). No significant

**Table 2** The changes of intraocular pressure, BMO–MRW and area from baseline

	Mean (SD) at baseline	Mean (SD) at first and second IOP elevations	95% CI	p-Value
<b>IOP</b>				
Normal (n=31)	16.29 (2.69)	37.29 (5.39)	–23.32 to –18.67	<0.001
		45.16 (6.46)	–31.69 to –26.04	<0.001
OHT (n=20)	20.35 (2.79)	41.05 (5.41)	–23.04 to –18.35	<0.001
		47.80 (5.38)	–29.88 to –25.01	<0.001
Glaucoma (n=53)	17.43 (3.63)	37.01 (6.34)	–21.83 to –17.32	<0.001
		46.45 (6.14)	–31.16 to –26.86	<0.001
<b>BMO–MRW</b>				
Normal (n=31)	287.46 (42.20)	280.82 (43.74)	0.12 to 13.17	0.05
		280.88 (42.36)	–0.31 to 13.48	0.06
OHT (n=20)	254.67 (45.38)	253.36 (49.52)	–8.2 to 10.84	1.00
		252.75 (51.90)	–7.78 to 11.62	1.00
Glaucoma (n=53)	174.36 (54.31)	166.85 (52.64)	3.54 to 11.46	<0.001
		167.43 (52.63)	1.97 to 11.87	0.003
<b>BMO area</b>				
Normal (n=31)	2.21 (0.38)	2.18 (0.38)	0, 0.07	0.05
		2.18 (0.38)	–0.01 to 0.07	0.21
OHT (n=20)	2.39 (0.75)	2.41 (0.75)	–0.05 to 0.01	0.18
		2.36 (0.70)	–0.09 to 0.15	1.00
Glaucoma (n=53)	2.52 (0.64)	2.53 (0.65)	–0.03 to 0.02	1.00
		2.52 (0.67)	–0.03 to 0.04	1.00

BMO, Bruch's membrane opening; MRW, minimum rim width; IOP, intraocular pressure; OHT, ocular hypertension.

change in BMO area was found at the first or second IOP elevation when compared with that at baseline in all groups (table 2).

### Intraobserver variability

The agreement of limit for intraobserver variability was from 5.096 (95% CI limit 2.607 to 7.585) to -6.896 (95% CI limit -9.385 to -4.407) for first IOP elevation, whereas for second IOP elevation, it was from 5.653 (95% CI limit 2.746 to 8.56) to -8.353 (95% CI limit -11.26 to -5.446).

### DISCUSSION

In this study, we analysed the changes in the neural tissues of ONH based on BMO-derived indices, as detected by SD-OCT, before and after acute IOP elevations. Our main finding is that acute IOP elevations resulted in significant reduction in neuroretinal rim width (measured by BMO-MRW) in glaucoma eyes but not in the healthy and ocular hypertensive eyes. In contrast, the BMO area (akin to optic disc size) did not change significantly in all groups.

In vivo imaging with SD-OCT provides a more objective assessment of ONH, particularly the disc margin, by using a reliable and consistent landmark like the BMO, compared with the subjective clinical identification of optic disc margin. BMO is believed to be a more consistent anatomic landmark for measuring various ONH-related parameters, such as the newly defined MRW.<sup>9 11</sup> It has been demonstrated that neuroretinal rim measurements based on BMO-MRW were superior to those based on clinical disc margin.<sup>11</sup>

### Thinner neuroretinal rim width in glaucoma at baseline and at IOP increments

We noted that the BMO-MRW was significantly thinner in glaucoma subjects when compared with that of OHT or normal controls at baseline. Our results are in agreement with findings obtained in previous investigations.<sup>11 17</sup> In a study involving 107 glaucomatous and 48 normal subjects, Chauhan *et al* reported BMO-MRW to be 42% smaller in glaucoma subjects than in controls.<sup>11</sup> Moreover, we found that glaucoma subjects demonstrated significant decrease in the BMO-MRW following acute IOP elevations, but this was not found in normal and OHT eyes. Jiang also reported that BMO-MRW was thinner in temporal and nasal quadrants of ONH in PACS eyes following acute IOP elevation (>15 mm Hg) by a darkroom prone provocative test.<sup>12</sup> Previous studies on animal<sup>18 19</sup> and enucleated human eyes<sup>20</sup> have shown similar results of prelaminar ONH tissues thinning. Agoumi *et al* reported that ONH surface change in humans due to acute IOP increase was compression of prelaminar tissue and not laminar displacement.<sup>5</sup>

We speculated that the nerve fibre layers (measured by BMO-MRW) at ONH may be compressed more against a stiffer sclera than a softer one during IOP increases (sandwich effect). Our preliminary and simplified finite element models showed that neuroretinal rim width, BMO-MRW was relatively more exposed to compression following acute IOP elevation in the presence of a stiffer peripapillary sclera (data not shown as further confirmation is needed). In this study, only glaucoma subjects demonstrated the BMO-MRW thinning following acute IOP elevations, which was not seen in other diagnoses. The glaucoma subjects in this study were significantly older and may have a stiffer peripapillary sclera than others.<sup>21</sup>

### No significant difference of optic disc size among groups and acute IOP increases

At baseline, we found that the BMO area (akin to optic disc size) was relatively large in glaucoma subjects, but it was not significantly different when compared with subjects with OHT and normal controls. Furthermore, we found that the BMO area did not change with acute IOP elevations for all diagnoses. Amini *et al* also demonstrated that there was no difference in BMO area between glaucoma and control subjects.<sup>22</sup> Similar results were found by Wu *et al* wherein they observed no change in optic disc size in a significant portion of patients with glaucoma during longitudinal follow-up of 5 years.<sup>23</sup> In contrast to the human studies, the animal studies revealed an enlargement of the scleral canal.<sup>7</sup> This may indicate that optic disc size changes may be varied largely based on biomechanical properties of the connective tissues, IOP level and exposure time of high IOP.

### Limitations

Limitations of our study include the potential variability of IOP elevations among the observers and the relatively short duration (2–3 min) of acute IOP elevation; however, the intraobserver and interobserver variability in our study was good, and we could also detect significant changes of the BMO-derived parameters.<sup>14</sup> Although it is plausible that BMO could migrate posteriorly with age, longitudinal data confirming this observation are lacking. The possibility of change in the LC position with IOP elevation or reduction contributing to the change BMO-MRW could also not be ruled out. The translaminar pressure dynamics play a role in the position of the LC surface relative to BMO.<sup>24</sup> A significant reduction in the posterior displacement and increase in the thickness of the LC and prelaminar tissue has been demonstrated following IOP reduction after glaucoma surgery. Conversely, the posterior movement of LC after IOP elevation can pull the prelaminar neural tissues causing reduction of BMO-MRW.<sup>25</sup> However, in this study, we did not look into the changes of the LC parameters like LC depth or curvature and their correlation with BMO-MRW. This study population was exclusively Chinese and therefore the results may not be generalised to other ethnic groups. Although the presence of cataract may affect OCT image quality, we excluded the subjects with low signal strength on imaging. It is also worthy to note the non-linear behaviour of BMO-MRW thinning with acute IOP elevations in almost all groups, as it could be representative of the well-established non-linear stiffening of ONH connective tissues with IOP, but this remains to be determined.<sup>26</sup> Because of this biomechanical complexity, we are unable to conclude as to whether increased thinning of BMO-MRW in glaucoma subjects would directly reflect connective tissue changes. Also, other factors such as the shape, position of the eye, cushioning effect of the surrounding retinal and choroid tissue might also influence the results. Our results need to be validated in longitudinal studies and techniques using in vivo strain and stiffness mapping as currently established and used in our laboratory.<sup>27</sup> Nevertheless, understanding changes in MRW with acute IOP may help us understand complex biomechanical interactions between neural and connective tissues and are relevant for glaucoma management.

In conclusion, compression of the nerve fibre layers of neuroretinal rim following acute IOP elevation was detected only in glaucoma subjects without changing the rim area. This suggests that the neural and connective tissue in subjects with glaucoma is more susceptible to acute IOP changes than seen in OHT and normal controls. The morphological changes of

neuroretinal rim area and width could reflect neural tissues and/or connective tissues elasticity, which is likely to play an important role in glaucomatous damage at the ONH.

**Acknowledgements** We thank Dr Thierry Chabin (Ophthalmologist, Sainte-Foy-Lès-Lyon, France) for providing the ophthalmodynamometer used in this study.

**Contributors** SS collected, cleaned and analysed the data, drafted and revised the paper. TAT contributed to the design and initiation of the project, designed data collection tools, monitored data collection, drafted and revised the paper. MB and EA contributed to the analysis and interpretation of data and revised the draft paper. SGT, ZL and DM contributed to the interpretation of data and revised the draft paper. NGS contributed to the analysis and interpretation of data for the work and revised the draft paper. TA and MJAG contributed to the design and initiation of the project, designed data collection tools, monitored data collection, contributed to the interpretation of data, drafted and revised the paper.

**Funding** This study was supported by the National University Singapore Young Investigator Award (MG; NUSYIA\_FY13\_P03; R-397-000-174-133) and the Singapore Ministry of Health's National Medical Research Council under its Singapore Translational Research Investigator Award (NMRC/STAR/0023/2014). The sponsor or funding organisation had no role in the design or conduct of this research. NGS was supported by the National Institute for Health Research (NIHR) Biomedical Research Centre based at Moorfields Eye Hospital National Health Service Foundation Trust and University College of London Institute of Ophthalmology.

**Disclaimer** The views expressed here are those of the author(s) and not necessarily those of the National Health Service, the National Institute for Health Research or the UK Department of Health.

**Competing interests** None declared.

**Ethics approval** SingHealth Centralized Institutional Review Board.

**Provenance and peer review** Not commissioned; externally peer reviewed.

© Article author(s) or their employer(s) unless otherwise stated in the text of the article) 2017. All rights reserved. No commercial use is permitted unless otherwise expressly granted.

## REFERENCES

- Heijl A, Leske MC, Bengtsson B, *et al.* Reduction of intraocular pressure and glaucoma progression: results from the early Manifest Glaucoma Trial. *Arch Ophthalmol* 2002;120:1268–79.
- Kass MA, Heuer DK, Higginbotham EJ, *et al.* The ocular hypertension treatment study: a randomized trial determines that topical ocular hypotensive medication delays or prevents the onset of primary open-angle glaucoma. *Arch Ophthalmol* 2002;120:701–13.
- Burgoyne CF, Downs JC, Bellezza AJ, *et al.* The optic nerve head as a biomechanical structure: a new paradigm for understanding the role of IOP-related stress and strain in the pathophysiology of glaucomatous optic nerve head damage. *Prog Retin Eye Res* 2005;24:39–73.
- Eid TE, Spaeth GL, Moster MR, *et al.* Quantitative differences between the optic nerve head and peripapillary retina in low-tension and high-tension primary open-angle glaucoma. *Am J Ophthalmol* 1997;124:805–13.
- Agoumi Y, Sharpe GP, Hutchison DM, *et al.* Lamellar and prelaminar tissue displacement during intraocular pressure elevation in glaucoma patients and healthy controls. *Ophthalmology* 2011;118:52–9.
- Sigal IA, Yang H, Roberts MD, *et al.* IOP-induced lamina cribrosa deformation and scleral canal expansion: independent or related? *Invest Ophthalmol Vis Sci* 2011;52:9023–32.
- Strouthidis NG, Fortune B, Yang H, *et al.* Effect of acute intraocular pressure elevation on the monkey optic nerve head as detected by spectral domain optical coherence tomography. *Invest Ophthalmol Vis Sci* 2011;52:9431–7.
- Girard MJ, Tun TA, Husain R, *et al.* Lamina cribrosa visibility using optical coherence tomography: comparison of devices and effects of image enhancement techniques. *Invest Ophthalmol Vis Sci* 2015;56:865–74.
- Reis AS, O'Leary N, Yang H, *et al.* Influence of clinically invisible, but optical coherence tomography detected, optic disc margin anatomy on neuroretinal rim evaluation. *Invest Ophthalmol Vis Sci* 2012;53:1852–60.
- Strouthidis NG, Fortune B, Yang H, *et al.* Longitudinal change detected by spectral domain optical coherence tomography in the optic nerve head and peripapillary retina in experimental glaucoma. *Invest Ophthalmol Vis Sci* 2011;52:1206–19.
- Chauhan BC, O'Leary N, Almobarak FA, *et al.* Enhanced detection of open-angle glaucoma with an anatomically accurate optical coherence tomography-derived neuroretinal rim parameter. *Ophthalmology* 2013;120:535–43.
- Jiang R, Xu L, Liu X, *et al.* Optic nerve head changes after short-term intraocular pressure elevation in acute primary angle-closure suspects. *Ophthalmology* 2015;122:730–7.
- Hodapp E PRI, Anderson DR. *Clinical decisions in glaucoma*. St Louis: Mosby, 1993.
- Tun TA, Thakku SG, Png O, *et al.* Shape changes of the Anterior Lamina cribrosa in normal, ocular hypertensive, and Glaucomatous eyes following acute intraocular pressure elevation. *Invest Ophthalmol Vis Sci* 2016;57:4869–77.
- Tun TA, Sun CH, Baskaran M, *et al.* Determinants of optical coherence tomography-derived minimum neuroretinal rim width in a normal Chinese population. *Invest Ophthalmol Vis Sci* 2015;56:3337–44.
- Thakku SG, Tham YC, Baskaran M, *et al.* A global shape index to characterize Anterior Lamina cribrosa morphology and its determinants in healthy indian eyes. *Invest Ophthalmol Vis Sci* 2015;56:3604–14.
- Danthurebandara VM, Vianna JR, Sharpe GP, *et al.* Diagnostic accuracy of glaucoma with sector-based and a new total profile-based analysis of neuroretinal rim and retinal nerve fiber layer thickness. *Invest Ophthalmol Vis Sci* 2016;57:181–7.
- Bellezza AJ, Hart RT, Burgoyne CF. The optic nerve head as a biomechanical structure: initial finite element modeling. *Invest Ophthalmol Vis Sci* 2000;41:2991–3000.
- Morgan WH, Chauhan BC, Yu DY, *et al.* Optic disc movement with variations in intraocular and cerebrospinal fluid pressure. *Invest Ophthalmol Vis Sci* 2002;43:3236–42.
- Yan DB, Coloma FM, Metheertraut A, *et al.* Deformation of the Lamina cribrosa by elevated intraocular pressure. *Br J Ophthalmol* 1994;78:643–8.
- Fazio MA, Grytz R, Morris JS, *et al.* Human scleral structural stiffness increases more rapidly with age in donors of African descent compared to donors of European descent. *Invest Ophthalmol Vis Sci* 2014;55:7189–98.
- Amini N, Miraftebi A, Henry S, *et al.* The relationship of the clinical disc margin and Bruch's membrane opening in normal and glaucoma subjects. *Invest Ophthalmol Vis Sci* 2016;57:1468–75.
- Wu Z, Xu G, Weinreb RN, *et al.* Optic nerve head deformation in glaucoma: a prospective analysis of optic nerve head surface and Lamina cribrosa surface displacement. *Ophthalmology* 2015;122:1317–29.
- Lee DS, Lee EJ, Kim TW, *et al.* Influence of translaminar pressure dynamics on the position of the anterior Lamina cribrosa surface. *Invest Ophthalmol Vis Sci* 2015;56:2833–41.
- Lee EJ, Kim TW, Weinreb RN. Reversal of Lamina cribrosa displacement and thickness after trabeculectomy in glaucoma. *Ophthalmology* 2012;119:1359–66.
- Girard MJ, Downs JC, Bottlang M, *et al.* Peripapillary and posterior scleral mechanics-part II: experimental and inverse finite element characterization. *J Biomech Eng* 2009;131:051012.
- Girard MJ, Strouthidis NG, Desjardins A, *et al.* In vivo optic nerve head biomechanics: performance testing of a three-dimensional tracking algorithm. *J R Soc Interface* 2013;10:20130459.



## Effect of acute intraocular pressure elevation on the minimum rim width in normal, ocular hypertensive and glaucoma eyes

Sourabh Sharma, Tin A Tun, Mani Baskaran, Eray Atalay, Sri Gowtham Thakku, Zhang Liang, Dan Milea, Nicholas G Strouthidis, Tin Aung and Michael JA Girard

*Br J Ophthalmol* published online May 10, 2017

---

Updated information and services can be found at:  
<http://bjo.bmj.com/content/early/2017/05/10/bjophthalmol-2017-31023>  
2

---

*These include:*

### References

This article cites 26 articles, 10 of which you can access for free at:  
<http://bjo.bmj.com/content/early/2017/05/10/bjophthalmol-2017-31023>  
2#BIBL

### Email alerting service

Receive free email alerts when new articles cite this article. Sign up in the box at the top right corner of the online article.

---

### Notes

---

To request permissions go to:  
<http://group.bmj.com/group/rights-licensing/permissions>

To order reprints go to:  
<http://journals.bmj.com/cgi/reprintform>

To subscribe to BMJ go to:  
<http://group.bmj.com/subscribe/>